

# **A comparison of accuracy of clinical tests and MRI in the diagnosis of meniscal and anterior cruciate ligament injuries**

Dr Micheni Jamlick Muthuuri

Consultant Orthopaedic and Trauma Surgeon

P.O Box 84074

Mombasa, Kenya.

Email: [michenimuthuuri@yahoo.com](mailto:michenimuthuuri@yahoo.com)

Tel +254722411757

ORCID No. 0000-0003-4866-6779

## **Abstract**

**Purpose:** The purpose of this study was to compare the accuracy of clinical examination versus magnetic resonance imaging (MRI) in the diagnoses of meniscal and anterior cruciate ligament (ACL) tears after trauma.

**Methods:** Between January 2011 and December 2015, 147 consecutive patients with previous history of knee injury were seen and evaluated clinically. One hundred and one were recruited for the study; out of these 52 knees were suspected to have meniscal tears while 36 knees were suspected to have ACL ruptures and 12 knees were unclear (equivocal). There were 68 males and 33 females. ) The average preoperative period for the patients was 3 months (range, 1month to 2 years) and their mean age was 35 years (range, 15 to 49 years). After initial clinical diagnosis some patients underwent arthroscopy without MRI (34) and some had MRI scanning before arthroscopy (67). The final diagnosis was made at arthroscopy on all patients. Accuracy, sensitivity, specificity, and positive and negative predictive values were calculated comparing clinical examination and MRI reporting.

**Results:** There was a wide variance between clinical diagnosis and MRI reportage for meniscal tears. Clinical examination had negative predictive value of 25% against 6% for MRI. Both had high sensitivity of (87% and 92%) and low specificity (32% and 50%, respectively). The differences were statistically significant ( $P = 0.0164$ ). On the contrary, there was little difference between clinical diagnosis and MRI diagnosis in the diagnosis of ACL raptures. There was a negative predictive value of 8% for clinical examination against 4% for MRI with a sensitivity of 92% and 96% respectively. Both have a high specificity (75% and 80%, respectively). There was no statistical difference between

the two modes of diagnosis ( $P = 0.6177$ ). MRI easily picked both injuries (ACL and meniscal) in the same knee which were difficult to differentiate clinically.

**Conclusions:** A careful clinical examination can safely diagnose almost all ACL injuries and most of the meniscal injuries. MRI should be reserved for more complicated and confusing cases. The routine ordering of an MRI scan of the knee before examination by a well-trained orthopaedic surgeon is not recommended. This is more so true in resource limited economies and public hospitals in the developing world.

Keywords

Accuracy, clinical, MRI, meniscal, ACL, tears

## Introduction

Meniscal and anterior cruciate ligament tears (ACL) are very common knee injuries among sports people and after falls. They are also reported as some of the most common indications for knee surgery[1]. The evaluation of these injuries begins with a thorough clinical examination, which include specific tests for meniscal and ACL injuries. This is commonly followed by Magnetic Resonance Imaging (MRI) scanning in order to increase the accuracy of diagnosis. Where the MRI is not available or when the finances are limited the surgeon may opt to directly do arthroscopy which serves for both diagnosis and treatment. It has been said that in the hands of a well-trained orthopaedic surgeon, diagnosis can be made accurately in 75% of such knees on the basis of the history alone[2, 3], This level of accuracy is slightly increased by performing specific clinical tests. Such tests have been reported to have high sensitivity and specificity values[1], which help reduce the use of MRI scanning. Due to its non-invasive nature, magnetic resonance imaging has currently become the most widely used method of detecting meniscal and ACL injuries for both orthopaedic surgeons and primary health-care cadre. It is reported to have a diagnostic accuracy of as high as 98% [4, 5]. In the primary health set up where the patient is reviewed by non-orthopaedist, there has been increased use of MRI scanning in [2, 3, 6]. However, magnetic resonance imaging scanning is expensive and very restricted particularly in the developing countries. Therefore, increasing and honing clinical skills is of paramount importance under these circumstances.

The final diagnosis is made at arthroscopic evaluation of the knee joint with intent to treat [7, 8].

This study has attempted to determine the accuracy of clinical examination against the accuracy of MRI reporting of ACL and meniscal injuries in a resource restricted environment. All the clinical tests were done by the author.

## **Materials and Methods**

### ***Patients***

Between January 2011 and December 2015, 147 patients with knee symptoms after injury were examined in by the author. Participants for the study were recruited on the basis of the history and the mechanism of injury and the specific tests and results of plain radiography. Exclusion criteria included those with peri-articular fractures and any other limb injuries, a history of knee surgery and clinical and radiographic signs of osteoarthritis or infection. All patients with abnormal findings on conventional radiography were also excluded from the study. Acutely injured knees were excluded. One hundred and one adult patients with an average age of 35 years (range, 15 to 49 years), were identified, signed a consent form, and were studied prospectively. These were 68 men and 33 women. Out of these, 67 patients underwent MRI examination before arthroscopy while the remaining 34 were taken straight for arthroscopy.

### **Clinical Evaluation**

All the 101 patients had a thorough history taken including the type and mechanism of injury. This was followed by a comprehensive physical examination including the special tests for ACL and meniscal injuries, on both the symptomatic and asymptomatic knees. Because most often, these injuries co-exist the entire battery of tests was done in every particular individual and recorded. When both injuries were suspected, it was recorded as so and recognised in the final results.

For suspected anterior cruciate ligament injury the examiner relied on the positivity of any of the following tests; the drawers test, the pivot test and the Lachman's tests. For suspected meniscal injury was suspected, the examiner relied on the positivity of any of the following tests; joint-line tenderness, the McMurray's tests and pain on forced flexion.

Thirty four knees bypassed MRI scanning and underwent definitive arthroscopic diagnosis. The remaining 67 underwent MRI scanning before arthroscopy. Magnetic resonance imaging scans were performed on a GE 1.5T MRI scanner (General Electric, USA). T1 weighted, T2 weighted, PD weighted, fat and water suppression sequences were performed on the knee in standard orthogonal planes. All the MRI scans were reported by two radiologists in the same firm (together or individually). The participants were distributed as shown in Table 1.

<b>Clinical Diagnosis</b>	<b>Number</b>	<b>Subjected To MRI</b>
Suspected Torn Meniscus	52	29
Suspected ACL	37	25
Equivocal	12	12
<b>TOTAL CASES</b>	<b>101</b>	<b>66</b>

*Table 1 Showing distribution of the participants*

### **Arthroscopy**

All the 101 participants underwent arthroscopy. The indications for arthroscopy were a torn meniscus or ruptured ACL either clinically or by MRI. The patients were prepared and consent taken according to the diagnosis. In most cases, arthroscopy was done for diagnosis with intention to treat. This was varied in those patients whose diagnosis was equivocal and who were taken for diagnostic arthroscopy. Those with torn meniscus had meniscal repair or partial meniscectomy depending on various considerations. Those that had ACL tear had ACL reconstruction done using the patella ligament of the same knee (bone-to-bone). The theatre inventory was adequate for all these procedures if required.

### **Statistical Analysis**

Diagnostic accuracy values such as sensitivity, specificity, positive and negative predictive values were calculated for the outcomes. The chi square test was used to determine the significance of any differences in the accuracy of diagnosis between clinical examination and magnetic resonance imaging. A p value of <0.05 was considered to be significant.

### ***Ethical Aspects***

The study design was approved by The Mombasa Hospital Ethical Committee. All participants were fully informed and signed a participation consent form. All procedures performed in this study were in accordance with the ethical standards of the institutional and national research committee and with the 1964 Helsinki declaration and its later amendments. There is no individual identifying information on any participants.

## Results

There were more males than females recruited in this study (2:1). There are two peaks; one between the age of 25 - 29 years and another between 40-50 years. This demographic distribution is illustrated in Figure 1.

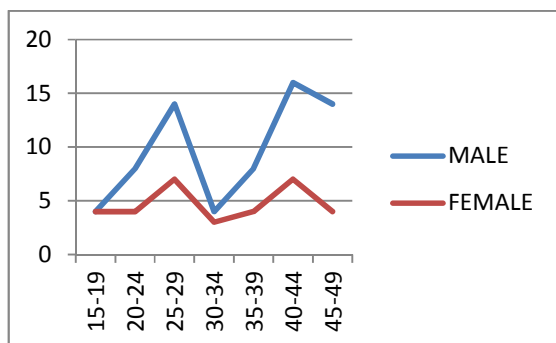


Figure 1 Showing demographics of the participants

Out of the 101 cases, the type of injury could not be determined in 12 of them. These 12 were included in the analysis of both meniscal and ACL injuries; the number analysed for meniscal injury was 64 and for ACL injury 49 (Table 2).

	Number (n)	MRI	NO MRI	ARTHROSCOPY
MENISCUS	52	29	23	52
EQUIVOCAL	12	12	0	12
ACL	37	25	12	37
TOTAL	101	66	35	101

Table 2 below show how the cases were distributed in the study

### Meniscal tears

Out of the 64 patients suspected to have meniscal tear, 52 had positive clinical tests while 12 were equivocal. All the 12 underwent MRI examination; also 29 out the 52 underwent MRI. Only 39 out of 52 clinically suspected tears were confirmed on arthroscopy compared to 34 out of 41 with MRI diagnosis. The causes of false positives in the clinical examination were ACL rupture and osteochondral lesions which constituted 52% of the false diagnosis. Five knees were normal. These results are summarised in table 3 below.

MENISCAL TEAR GROUP: ARTHROSCOPIC DIAGNOSIS

	CLINICAL	%		MRI	%
MENISCAL TEAR	39	61		34	83
ACL Rapture	7	11		1	2
Osteochondral lesions	6	9		2	5
Normal knees	5	8		1	2
Adhesions/Plicae	4	6		1	2
Others (FB, swellings etc.)	3	5		2	5
TOTAL	64	100		41	100

Table 3 summarising the findings at arthroscopy on knees suspected to have meniscal tear (52) and those that were equivocal (12) (both clinically and by MRI scanning).

The positive predictive value was 75% (94% MRI). The sensitivity of clinical examination is 87% (92% of MRI). Both have low specificity of 25% and 50% respectively. The differences between clinical examination and MRI scanning were statistically significant (P-value 0.0164). This analysis is well demonstrated in Table 4.

TEST	CLINICAL	MRI	TOTALS
True positive	39	34	73
False positive	13	2	15
False negative	6	3	9
True negative	6	2	8
TOTAL	64	41	105
		<b>P VALUE</b>	<b>0.0164</b>
	%	%	
POSITIVE PREDICTIVE VALUE	75	94	
SENSITIVITY	87	92	
SPECIFICITY	32	50	

Table 4 showing the analysis of the meniscal injury cohort

### ACL rupture

Out of the 49 patients potentially suspected to have ACL rupture (37 clinically positive and 12 that were equivocal); only 39 tears were confirmed by arthroscopy in this group. Arthroscopic findings in this group showed more agreement between clinical examination and MRI findings. Again osteochondral lesions were a diagnostic challenge for MRI with 2 false positives. The main challenge for the clinical examination was four patients with meniscal injury who had positive shifting pivot test. The other knee was normal. These results are summarised in table 5.

ACL GROUP: ARTHROSCOPIC DIAGNOSIS					
DIAGNOSIS	CLINICAL	%		MRI	%
ACL Rupture	34	69		30	81
Normal knees	5	10		2	5
Torn Meniscus	4	8		2	5
Osteochondral lesions	3	6		2	5
Adhesions/Plicae	2	4		1	3
Others (FB, swellings etc.)	1	2		1	3
TOTAL	49	100		37	100

*Table 5 showing the final diagnosis after arthroscopy on all cases suspected to have ACL rupture (for both clinical and MRI diagnosis)*

In this group both the positive predictive value and sensitivity for clinical examination was 92% (96% MRI). The specificity was 75% (80% MRI). The differences for accurate diagnosis between clinical examination and MRI scanning for ACL rupture was not statistically significant (P-value 0.6177). These findings are summarised in Table 6.

<b>ACL RAPTURES</b>		
TEST	CLINICAL	MRI
True positive	34	30
False positive	3	4
False negative	7	1
True negative	5	2
TOTAL	49	37
	<b>P VALUE</b>	<b>0.6177</b>
POSITIVE PREDICTIVE VALUE	92%	96%
SENSITIVITY	92%	96%
SPECIFICITY	75%	80%

*Table 6 showing the analysis of the ACL rapture cohort*

## **Discussion**

### **Meniscal tears**

Meniscal and ACL tears occur in young people as a result of injury from sports or accidents. The same maybe the aetiology in the elderly but the force of impact may be small and often ignored both by the patient and the clinician [9]. Provocative tests such as McMurray's test, elicit pain symptoms from a torn meniscus and may demonstrate a palpable click at the joint line[10]. The McMurray test is the most widely used test, and it is found to be positive in 58% of knees with a torn meniscus [11]. Joint-line tenderness is present in 77% to 85% of meniscal tears cases [11-13] and is thought to be the most accurate. Therefore, despite the wide use [1, 6, 14] of these manoeuvres, their specificity and diagnostic accuracy are low. This study used either a positive McMurray's test or joint line tenderness in concurrence for clinical diagnosis of meniscal tear with a positive predictive value of 75%, sensitivity of 87% and specificity of 32%. When the affected knee was subjected to MRI scanning, the positive predictive value increased to 94%, sensitivity to 92% and specificity of 50%.

Most of the reports describing the various clinical tests are old and few studies were set to compare the diagnostic accuracy of magnetic resonance imaging and arthroscopy [7, 8, 13, 15]. In these studies, the sensitivity and specificity of McMurray test rarely exceed the level of 80%. A high rate of false-positive findings is reported and yet their diagnostic accuracy does not improve with the examiner's experience [16]. Therefore, in order to improve diagnostic accuracy in the detection of meniscal tears, MRI scanning was recommended. While it has been argued that on the basis of the high value of negative findings on MRI, the same should be used for screening in order to avoid unnecessary arthroscopy [17]; MRI has a significant cost and it is not therapeutic while arthroscopy is both



diagnostic and therapeutic. In resource depleted countries a well performed clinical examination should triage patients for non-operative treatment and those for arthroscopy with intention to treat.

### **ACL rapture**

Knee instability is assessed with anterior drawers test, Lachman's test and pivot-shifting test. Most of the patients in this study were seen several weeks after injury, making examination in the office set up feasible. The Lachman, anterior-drawer, and pivot-shift tests were done without anaesthesia, comparing the injured knee with the normal knees. For the clinical diagnosis, any of the three tests were required to be unequivocal. The study particularly relied on anterior drawers test and Lachman's test in concurrence.

Many studies have recorded the predictive value and reproducibility of individual clinical tests (particularly Lachman test) and MRI imaging in diagnosing acute ACL ruptures [18-20]. DeHaven (1980) compared the results of arthroscopy with clinical tests (anterior drawer, pivot-shift, anteromedial rotatory instability, and Lachman tests) and found false negative results to be between 16% (Lachman) and 84% (the other three clinical tests) in the conscious patients [21]. The pivot-shift test improved to 16% false-negative results and the Lachman test reached 100% accuracy under anaesthesia.

In this study where all the patients were conscious, a battery of clinical tests (anterior drawer, Lachman and pivot-shift tests) was employed to make a clinical diagnosis. The negative predictive value was 8% with a sensitivity of 92%. This slightly improved with MRI scanning (4% and 96% respectively). The differences were not statistically significant (P value = 0.6177). This compares well with a blind prospective study of 750 patients by Liu et al 1995, which showed 90% accuracy of Lachman test in the diagnosis of ACL tears [22]. GeIb et al, 1994 compared MRI and clinical examinations in 67 patients; the Lachman test showed 100% sensitivity and specificity compared with 94% sensitivity and 82% specificity for MRI scanning. He concluded that MRI had contributed to the management of only 11 (16%) of these patients [23]. Wertheim et al (1994) after a prospective study of 50 patients, found that in no case did MRI findings change the decision to proceed with surgery [24]. Our study has shown the reproducibility of an experienced examiner performing clinical examination is comparable to MRI scanning. The Lachman's test provided the best predictive value of the clinical signs. However, Lachman's test may sometime be difficult to do particularly in large limbs which are difficult to grasp. MRI was 96% sensitive in detecting ACL pathology, but specificity significantly decreased in the presence of other pathology, particularly osteochondral lesions.

MRI is expensive and poorly tolerated by many patients. In countries where cost is a major consideration and causes an impasse in the delivery of quality health care, clinical assessment is of

critical importance as its cheaper, faster and patient tolerated. The main argument for preoperative MRI is the detection of associated meniscal and other pathology in order to plan definitive treatment, particularly in situations of scant inventory of orthopaedic implants and supplies.

### **Arthroscopy**

Each arthroscopic operation was performed by the author.

At arthroscopy, a meniscus was considered to be torn if there was a cleavage on the substance of the meniscus simple or complex, obvious or by probing. A cruciate ligament was considered to be torn if it was completely disrupted at mid-substance or detached from either femur or tibia, or if excessive laxity (from an internal tear) could be demonstrated with a probe. Arthroscopic diagnoses is operator dependent and accuracy is reported to be around 95% [25]. In this study arthroscopic diagnosis was accepted as the best representation of the true status of the menisci and cruciate ligaments and was thus used to determine the reliability of clinical examination and magnetic resonance imaging.

### **Conclusion**

**We conclude** that in an injured knee, when the clinical diagnosis is ambivalent an MRI examination is necessary to determine the injury and plan treatment. We also conclude that the diagnosis and the decision to reconstruct a complete ACL rupture can reliably be made clinically without the added expense of preoperative MRI. There will be those patients who will be misdiagnosed, particularly if the examiner is not experienced. A detailed informed consent must always be obtained hinged on the expectation of both the patient and the doctor (including a negative arthroscopic result).

The routine ordering of an MRI scan of the knee before examination by a well-trained orthopaedic surgeon is not recommended. This is more so true in resource limited economies and public hospitals in the developing world.

### **References**

1. Howell, G., *Clinical presentation of the knee*. Oxford textbook of orthopedics and trauma, 2002. **2**: p. 1108-13.
2. DeHaven, K.E. and H. Collins, *Diagnosis of internal derangements of the knee. The role of arthroscopy*. J Bone Joint Surg Am, 1975. **57**(6): p. 802-810.
3. Daniel, D., Daniels, E. and Aronson D et al, *The diagnosis of meniscus pathology*. Clinical orthopaedics and related research, 1982. **163**: p. 218-224.
4. Gray, S.D., P.A. Kaplan, and R.G. Dussault, *Imaging of the knee: current status*. Orthopedic Clinics of North America, 1997. **28**(4): p. 643-658.
5. McNally, E.G., et al., *Role of magnetic resonance imaging in the clinical management of the acutely locked knee*. Skeletal radiology, 2002. **31**(10): p. 570-573.

6. Bollen, S., *How I examine the knee*. Current Orthopaedics, 2000. **14**(3): p. 189-192.
7. Gillies, H. and D. Seligson, *Precision in the diagnosis of meniscal lesions: a comparison of clinical evaluation, arthrography, and arthroscopy*. J Bone Joint Surg Am, 1979. **61**(3): p. 343-346.
8. Ireland, J., E. Trickey, and D. Stoker, *Arthroscopy and arthrography of the knee: a critical review*. Bone & Joint Journal, 1980. **62**(1): p. 3-6.
9. Matheson GO, M.J., Taunton JE, et al, *Musculoskeletal injuries associated with physical activity in older adults*. Medicine and science in sports and exercise, 1989. **21**(4): p. 379-385.
10. McMurray, T., *The semilunar cartilages*. British Journal of Surgery, 1942. **29**(116): p. 407-414.
11. Anderson, A.F. and A.B. Lipscomb, *Clinical diagnosis of meniscal tears Description of a new manipulative test*. The American journal of sports medicine, 1986. **14**(4): p. 291-293.
12. Shakespeare, D. and H. Rigby, *The bucket-handle tear of the meniscus. A clinical and arthrographic study*. Bone & Joint Journal, 1983. **65**(4): p. 383-387.
13. Eren, O.T., *The accuracy of joint line tenderness by physical examination in the diagnosis of meniscal tears*. Arthroscopy: The Journal of Arthroscopic & Related Surgery, 2003. **19**(8): p. 850-854.
14. Insall, J. and W. Scott, *Surgery of the knee. vol. 1*. New York: Churchill Livingstone, 2001: p. 190.
15. Rose, N.E. and S.M. Gold, *A comparison of accuracy between clinical examination and magnetic resonance imaging in the diagnosis of meniscal and anterior cruciate ligament tears*. Arthroscopy: The Journal of Arthroscopic & Related Surgery, 1996. **12**(4): p. 398-405.
16. Mink, J.H., T. Levy, and J. Crues 3rd, *Tears of the anterior cruciate ligament and menisci of the knee: MR imaging evaluation*. Radiology, 1988. **167**(3): p. 769-774.
17. Elvenes, J., et al., *Magnetic resonance imaging as a screening procedure to avoid arthroscopy for meniscal tears*. Archives of orthopaedic and trauma surgery, 2000. **120**(1-2): p. 14-16.
18. Boeree NR, W.A., Ackroyd CE et al, *Magnetic resonance imaging of meniscal and cruciate injuries of the knee*. Bone & Joint Journal, 1991. **73**(3): p. 452-457.
19. Fischer SP, F.J., Del Pizzo W et al, *Accuracy of diagnoses from magnetic resonance imaging of the knee. A multi-center analysis of one thousand and fourteen patients*. J Bone Joint Surg Am, 1991. **73**(1): p. 2-10.
20. Anderson, A.F. and A.B. Lipscomb, *Preoperative instrumented testing of anterior and posterior knee laxity*. The American journal of sports medicine, 1989. **17**(3): p. 387-392.
21. Dehaven, K.E., *Diagnosis of acute knee injuries with hemarthrosis*. The American journal of sports medicine, 1980. **8**(1): p. 9-14.
22. Liu, S.H., et al., *The diagnosis of acute complete tears of the anterior cruciate ligament. Comparison of MRI, arthrometry and clinical examination*. Bone & Joint Journal, 1995. **77**(4): p. 586-588.
23. Gaisgow, S. and A. Sapega, *The clinical value and cost effectiveness of magnetic resonance imaging (MRI) in the management of knee disorders in a sports medicine practice*. Orthop Trans, 1994. **18**: p. 1012.
24. Wertheim, S., R. Klaus, and S. Gillespie, *The role of MRI in the treatment of acute knee injuries*. Orthopedic Transactions, 1994. **18**: p. 1013.
25. Reicher, M.A., L.W. Bassett, and R.H. Gold, *High-resolution magnetic resonance imaging of the knee joint: pathologic correlations*. American Journal of Roentgenology, 1985. **145**(5): p. 903-909.